

# Besifloxacin Ophthalmic Suspension 0.6% in the Treatment of Bacterial Keratitis: A Retrospective Safety Surveillance Study

Barry A. Schechter,<sup>1</sup> Jai G. Parekh,<sup>2</sup> and William Trattler<sup>3</sup>

## Abstract

**Purpose:** The objective of this study was to collect and evaluate retrospective safety information about the use of besifloxacin ophthalmic suspension 0.6% for the treatment of bacterial keratitis.

**Methods:** This was a retrospective, postmarketing surveillance study conducted at 10 clinical centers in the United States. The study population included 142 patients treated with besifloxacin ophthalmic suspension 0.6% for bacterial keratitis in one or both eyes. For perspective, data on 85 patients treated at these centers with moxifloxacin ophthalmic solution 0.5% for bacterial keratitis were also included. The analysis was designed to measure the types and rates of adverse events (AEs) reported during the treatment of bacterial keratitis with besifloxacin ophthalmic suspension 0.6%. Other treatment outcomes of interest included the development of corneal scarring and corneal neovascularization, measured or presumed bacterial eradication, ending visual acuity, and duration of pain before and after treatment.

**Results:** There was one reported AE of mild superficial punctate keratitis in a patient using besifloxacin ophthalmic suspension 0.6%. The difference in AE frequencies between groups was not significant ( $P > 0.999$ ). Additional treatment outcomes were similar for both groups. Limitations of this report include the retrospective nature of the study.

**Conclusions:** These retrospective data suggest that besifloxacin ophthalmic suspension 0.6% was well tolerated when included in the treatment of bacterial keratitis; no serious AEs were reported. A prospective clinical trial is needed to better isolate the contribution of besifloxacin to the therapeutic outcome and to confirm these observations.

## Introduction

**B**ACTERIAL KERATITIS is a serious and potentially sight-threatening ocular condition of the cornea that can result in scarring and opacification with loss of visual acuity (VA) and occasionally, corneal perforation. The normal cornea is lubricated by the precorneal tear layer, and is transparent and lustrous; however, a breach or defect in the corneal epithelium can lead to microbial invasion, inflammation, and underlying damage to the corneal stroma.<sup>1</sup> Patients present acutely and often experience considerable pain and distress.<sup>1</sup> Keratitis must be viewed as a true medical emergency and should be treated aggressively to limit subsequent damage and potential loss of vision.

Keratitis is uncommon in the absence of a predisposing condition. Risk factors such as ocular trauma, chronic ocular

surface disease, previous ocular surgery, other ocular defects, and systemic disease such as diabetes or immunosuppressive treatment compromise the eye and have been associated with infectious keratitis.<sup>1-3</sup> Contact lens use is the greatest predisposing factor for infectious keratitis in developed countries, accounting for 33%–50% of reported cases.<sup>2,3</sup>

While the spectrum of bacterial keratitis may vary by geography and/or climate, gram-positive organisms are the most frequently cultured pathogens in infectious keratitis, reported in 65%–90% of cases.<sup>4</sup> The principle gram-positive cocci cultured from infectious corneal ulcers are *Staphylococcus epidermidis*, *Staphylococcus aureus*, *Streptococcus pneumoniae*, and *Streptococcus veridans* group.<sup>4</sup> Among contact lens users, *Pseudomonas aeruginosa* is the most prevalent gram-negative pathogen. *P. aeruginosa* can cause

<sup>1</sup>Florida Eye Microsurgical Institute, Boynton Beach, Florida.

<sup>2</sup>The New York Eye & Ear Infirmary/New York Medical College, Brar-Parekh Eye Associates, Woodland Park, New Jersey.

<sup>3</sup>Center for Excellence in Eye Care, Miami, Florida.

a rapidly progressive infiltrate with suppuration and necrosis.<sup>4</sup> Pathogens such as *P. aeruginosa*, *S. aureus*, and *S. pneumoniae* secrete toxic cytolysins and proteases that directly or indirectly mediate epithelial and underlying stromal damage. Once these toxins are produced, loss of healthy tissue may occur despite antibiotic therapy.<sup>5</sup> Failure to implement prompt, aggressive, and appropriate treatment has been correlated with poor visual outcomes.<sup>6-9</sup>

Treatment of bacterial keratitis has traditionally consisted of frequent administration of high-concentration (fortified) antibacterial agents or a combination of topical antibacterial agents to better cover the infectious agent(s). Fourth-generation fluoroquinolones are broad-spectrum antibiotics that have emerged as effective monotherapeutic alternatives to this paradigm.<sup>10-13</sup> Recent treatment updates characterize fourth-generation fluoroquinolones as the standard of care for management of infiltrates with small corneal defects (up to 2 mm in size); while fortified antibiotics are recommended for more severe ulcers, those >2 mm or with sight-threatening potential.<sup>4</sup>

Besifloxacin is an advanced generation topical fluoroquinolone, specifically an 8-chloro-fluoroquinolone with broad spectrum *in vitro* activity against a wide range of gram-positive and gram-negative ocular pathogens, including multi-drug-resistant staphylococcal strains.<sup>4,14-18</sup> A topical ophthalmic suspension of besifloxacin 0.6% (Besivance™; Bausch + Lomb, Rochester, NY) was approved by the U.S. Food and Drug Administration for the treatment of bacterial conjunctivitis.<sup>19</sup> The mechanism of action of besifloxacin involves balanced targeting of bacterial DNA gyrase and topoisomerase IV, rendering the agent highly potent while minimizing resistance potential.<sup>20,21</sup> Besifloxacin is formulated with DuraSite, a mucoadhesive polymer delivery system (DuraSite®; InSite Vision, Inc., Alameda, CA) that prolongs the residence time of the drug on the ocular surface.<sup>22-24</sup>

In clinical studies of besifloxacin ophthalmic suspension, 0.6% for the treatment of bacterial conjunctivitis, high eradication rates were observed against infections attributed to those species that are common pathogens in bacterial keratitis, including *P. aeruginosa*.<sup>25</sup> In rabbit models of keratitis due to infection with methicillin-resistant *S. aureus* (MRSA) or quinolone-resistant *P. aeruginosa*, treatment with besifloxacin ophthalmic suspension 0.6% led to a significant decrease in colony-forming units (CFU) of the infecting agent in corneal tissue with the decrease in CFUs being significantly greater in the besifloxacin-treated eyes compared with gatifloxacin- and moxifloxacin-treated eyes.<sup>26-28</sup> These studies suggest that besifloxacin could be a useful antibacterial agent in the treatment of bacterial keratitis. Studies on the use of besifloxacin to treat keratitis in human eyes, however, have not yet been published, apart from a single case report that described the resolution of a severe case of keratitis, presumably due to *P. aeruginosa* infection, with a regimen that included besifloxacin ophthalmic suspension.<sup>29</sup>

The objective of this postmarketing surveillance study was to gain safety information on the use of besifloxacin ophthalmic suspension 0.6% for the treatment of keratitis from several clinical centers. For perspective, data were also collected on patients using moxifloxacin ophthalmic solution 0.5% (Vigamox®; Alcon Laboratories, Inc., Fort Worth, TX) for the treatment of keratitis from the same centers.

## Methods

### Study design

This multicenter, retrospective, surveillance study was designed to evaluate data from patients prescribed either topical besifloxacin ophthalmic suspension 0.6% or moxifloxacin ophthalmic solution 0.5% for the treatment of bacterial keratitis. Data were planned to be collected from 10 clinical sites in the United States in a maximum of 250 eyes (150 besifloxacin ophthalmic suspension 0.6%, 100 moxifloxacin ophthalmic solution 0.5%). Retrospective analysis included consecutive cases treated after June 1, 2009.

Chart reviews were conducted by the investigating physician or a designated staff member at each site. Most investigators were ophthalmologists with fellowship training in corneal and external disease. In each case included, the initial diagnosis of bacterial keratitis was made at the clinician's discretion based on their usual standard of practice. Likewise, cultures were performed (or not) at the clinician's discretion. Data on demographics, case details about the patients' bacterial keratitis, relevant comorbid conditions, all topical ophthalmic medications utilized, treatment outcomes, and drug-related adverse events (AEs) were recorded using an electronic data collection form for each patient.

Treatment outcomes included evidence of corneal scarring, corneal neovascularization, and the investigator's assessment of bacterial eradication (measured or presumed). VA before and after treatment and duration of pain were assessed. AEs were classified according to severity (mild: did not interfere with normal activity; moderate: interfered with normal activity but patient could continue activity; severe: normal activity could not be continued).

In adherence to the Declaration of Helsinki standards for ethical research, all patient information was de-identified. Since this was a retrospective study, informed consent requirements were waived by the Institutional Review Boards.

### Analysis

The primary safety endpoint for this surveillance study was the occurrence of drug-related AEs.

All summaries were done at eye level. Summaries for continuous variables included sample size, mean, standard deviation, median, minimum and maximum. Discrete variables included tabulation of frequencies and percentages. Percentages were based on nonmissing values for each category.

Fisher's exact test was used to compare AE rates with besifloxacin and the comparator. Between-treatment differences in etiologic factors, frequency and duration of antibacterial use, characteristics of the baseline keratitis, and corneal outcomes were evaluated using chi-square test or Fisher's exact test (2-tailed) as appropriate. All statistical tests were carried out using a 2-sided  $\alpha=0.05$ , and all confidence intervals were estimated with 95% confidence. All analyses were conducted using SAS software version 9.1 or higher (SAS, Inc., Cary, NC).

## Results

A total of 227 case reports (227 eyes in 227 patients;  $n=142$  for besifloxacin,  $n=85$  for moxifloxacin) were

collected from 10 clinical sites in the United States. Three centers provided besifloxacin cases only ( $n=8$ ), while all other centers provided both besifloxacin and moxifloxacin cases ( $n=134$  and  $n=85$ , respectively).

Baseline patient characteristics, contact lens wear, and relevant etiological factors were comparable between treatment groups (Table 1). The median age was 39.5 (range, 11–96) years for the besifloxacin group and 41.0 (range, 16–91) years for the moxifloxacin group. The majority of patients were women, and more than half of patients in each treatment group wore contact lenses. More than 30% of patients in each cohort had no known etiological factors. A slightly higher proportion of patients treated with moxifloxacin had trauma or previous corneal surgery ( $P=0.001$ ).

The baseline clinical characteristics of the keratitis were also comparable between treatment groups. The distribution of corneal lesion size did not differ between treatments ( $P=0.320$ ), with the majority ( $>60\%$ ) of patients in both treatment groups having small lesions ( $<10\%$  of the corneal surface). Other baseline clinical characteristics are shown in Fig. 1 and did not differ between treatment groups ( $P\geq 0.268$ ) (Fig. 1). Ulceration of the epithelium and conjunctival hyperemia was reported for the majority of patients in each group (Fig. 1). Corneal lesions were cultured in 25 (11%) of the cases. Of these cultures, 9 failed to grow bacteria, 14 grew gram-positive bacteria, most often coagulase negative staphylococci (CoNS), and 3 grew *P. aeruginosa*, including one polymicrobial culture that also grew CoNS and enterococcus.

The frequency and duration of antibacterial use varied but did not differ between treatment groups ( $P\geq 0.268$ ). The median duration of treatment with each of the fluoroq-

uinolones being studied was 15 days. Roughly one-third of eyes were treated with a maximum dose frequency of 5 or more times per day. The final dosing frequency for the majority of patients was four times daily (QID) in both treatment groups (Table 2). Many patients in both treatment groups were treated with additional topical ophthalmic antibacterials at various dosing regimens, and a few were prescribed oral antibiotics. Five patients in each group used topical non-steroidal anti-inflammatory drugs (NSAIDs). Topical corticosteroids were additionally used in 13 besifloxacin-treated patients and in 12 moxifloxacin-treated patients.

For the primary endpoint, there was a single ocular AE noted, one case of mild punctate keratitis in a patient treated with besifloxacin along with another antibacterial for a large corneal ulcer. The case resolved without scarring or neovascularization. The difference in drug-related AE frequencies between groups was not significant ( $P>0.999$ ).

Treatment outcomes, including evidence of corneal scarring, corneal neovascularization, and investigator's assessment of bacterial eradication, were similar for all patients treated with either besifloxacin or moxifloxacin ( $P\geq 0.208$ ). Corneal scarring was evident in 23.2% of patients in the besifloxacin group and 29.4% in the moxifloxacin group (Fig. 2). Corneal neovascularization was noted in less than 2% of patients in either group (Fig. 2). Investigators reported high rates of bacterial eradication (95.8% besifloxacin vs. 91.8% moxifloxacin; Fig. 3). Most reports were based on clinical observations, and few were culture confirmed.

VA findings before and after treatment demonstrated similar improvements in both groups with 68.3% of besifloxacin-treated patients and 64.7% of moxifloxacin-treated patients having 20/30 or better VA at the end of treatment (Fig. 4) and no difference between treatments in the distribution of VA ( $P=0.311$ ). The mean duration of reported pain was similar between groups (15.4 days besifloxacin vs. 12.9 days moxifloxacin,  $P=0.661$ ).

TABLE 1. BASELINE PATIENT CHARACTERISTICS, CONTACT LENS WEAR, AND RELEVANT ETIOLOGICAL FACTORS

|   | Besifloxacin<br>(n=142) | Moxifloxacin<br>(n=85) |
|---|-------------------------|------------------------|
| Age at first day of treatment, year             |                         |                        |
| Mean (SD)                                       | 43.9 (21.2)             | 42.9 (20.5)            |
| Median (range)                                  | 39.5 (11–96)            | 41.0 (16–91)           |
| Gender, n (%)                                   |                         |                        |
| Male  | 53 (37.3)               | 37 (43.5)              |
| Female  | 89 (62.7)               | 48 (56.5)              |
| Contact lens wear, n (%) <sup>a</sup>           |                         |                        |
| None  | 61 (43.0)               | 35 (41.2)              |
| Soft, daily                                     | 47 (33.1)               | 32 (37.6)              |
| Soft, extended                                  | 26 (18.3)               | 8 (9.4)                |
| Soft, continuous                                | 3 (2.1)                 | 5 (5.9)                |
| Rigid   | 0                       | 2 (2.4)                |
| Relevant etiologic factors, n (%)               |                         |                        |
| Trauma or previous corneal surgery <sup>b</sup> | 9 (6.3)                 | 17 (20.0)              |
| Aqueous tear deficiency                         | 8 (5.6)                 | 5 (5.9)                |
| Immunodeficiency                                | 1 (0.7)                 | 2 (2.4)                |
| Recent corneal disease                          | 8 (5.6)                 | 4 (4.7)                |
| Malposition of eyelids                          | 3 (2.1)                 | 1 (1.2)                |
| Other   | 9 (6.3)                 | 2 (2.4)                |
| Unknown   | 43 (30.3)               | 32 (37.6)              |

<sup>a</sup>Contact lens data not available for 5 subjects in each treatment group.

<sup>b</sup> $P=0.001$  for the difference between treatments. There were no other differences between treatments in etiologic factors. SD, standard deviation.

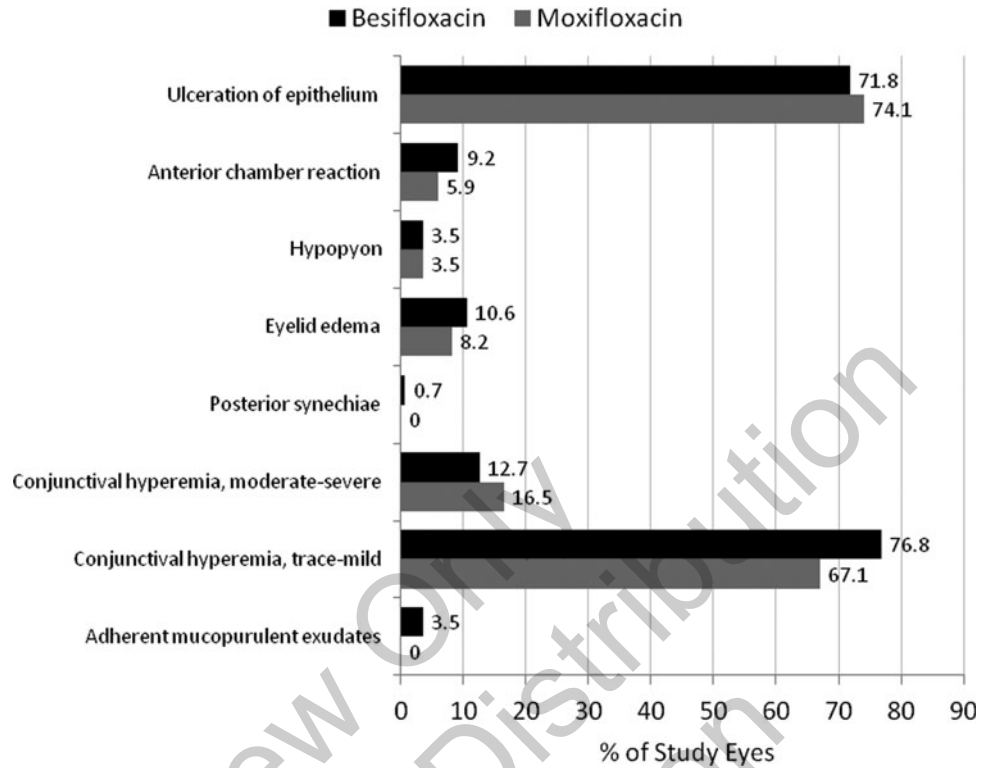
## Discussion

This retrospective chart review is the first study to evaluate the safety of besifloxacin ophthalmic suspension 0.6% when used in the treatment of bacterial keratitis. The findings did not identify any safety issues with the use of besifloxacin for this indication, and overall safety was similar to that of moxifloxacin ophthalmic solution 0.5%. Investigator-reported bacterial eradication was high for both treatments, and about two-thirds of patients reported VA of 20/30 or better at the end of treatment. Outcomes for corneal scarring, corneal neovascularization, or duration of pain were also similar between treatment groups.

The safety findings of this retrospective study are consistent with those reported in larger prospective, controlled studies of besifloxacin ophthalmic suspension 0.6% used for bacterial conjunctivitis.<sup>30–33</sup> Although the conjunctivitis trials entailed less frequent administration and shorter duration of therapy, the safety profile noted with longer and more frequent administration in the current analysis is consistent with the results from the bacterial conjunctivitis studies.

The safety findings of this study are also consistent with studies of besifloxacin when used as prophylaxis against infection in the surgical setting. A retrospective chart review of LASIK surgery cases where besifloxacin ophthalmic

**FIG. 1.** Baseline clinical characteristics of keratitis in both treatment groups.



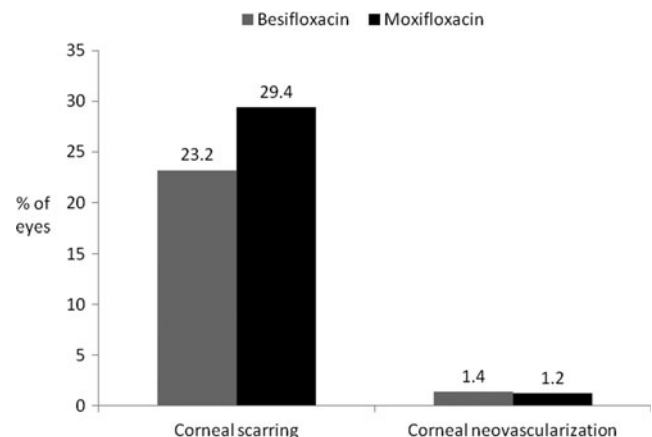
suspension 0.6% was used as prophylactic medication found no adverse drug reactions in 534 besifloxacin eyes treated an average of 8.6 days, administered 3 (50.2%) or 4 (38.6%) times daily.<sup>34</sup> In cases where besifloxacin was used intraoperatively (31.8%), besifloxacin was instilled either before flap creation and/or after flap replacement. Similarly, 2 chart reviews of routine cataract surgery cases—a retrospective review<sup>35</sup> and a prospective review (Majmudar PA and Comstock TL, data presented at the 2013 meeting of the American Society of Cataract and Refractive Surgery)—including a combined total of 826 eyes treated with besifloxacin, found that the prophylactic use of besifloxacin ophthalmic suspension 0.6% was not associated with any significant safety concerns. Mean duration of besifloxacin treatment was 12.0 days in the retrospective study and 14.7 days in the prospective study, and most patients (58.8% and 70.5%) were administered besifloxacin thrice daily.

There were also no AEs reported with the use of besifloxacin ophthalmic suspension 0.6% in a prospective, randomized, parallel-group, investigator-masked study of 58 patients undergoing routine cataract surgery.<sup>36</sup> In that study, patients received besifloxacin or moxifloxacin QID starting 3 days before surgery and continuing for 7 days postoperatively. Changes in central corneal thickness, endothelial cell count, and corneal staining, evaluated on postoperative days 7 and 28, were negligible with no difference between treatments. Finally, a prospective, contralateral eye, double-masked

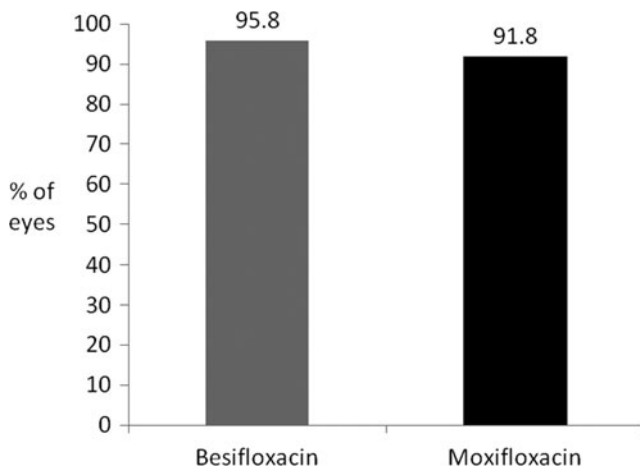
**TABLE 2.** FREQUENCY AND DURATION OF ANTIBACTERIAL USE

|   | Besifloxacin<br>(n = 142) | Moxifloxacin<br>(n = 85) |
|---|---------------------------|--------------------------|
| Initial frequency of antibacterial use, n (%) |                           |                          |
| 1 time daily                                  | 1 (0.7)                   | 1 (1.2)                  |
| 2 times daily                                 | 5 (3.5)                   | 5 (5.9)                  |
| 3 times daily                                 | 9 (6.3)                   | 8 (9.4)                  |
| 4 times daily                                 | 60 (42.3)                 | 24 (28.2)                |
| 5–8 times daily                               | 21 (14.8)                 | 15 (17.6)                |
| >8 times daily                                | 12 (8.5)                  | 11 (12.9)                |
| Data missing                                  | 34 (23.9)                 | 21 (24.7)                |
| Duration of antibacterial use, days           |                           |                          |
| Mean (SD)                                     | 23.6 (27.5)               | 28.2 (49.6)              |
| Median (range)                                | 15 (3–200)                | 15 (2–380)               |
| Final frequency of antibacterial use, n (%)   |                           |                          |
| 1 time daily                                  | 1 (0.7)                   | 1 (1.2)                  |
| 2 times daily                                 | 5 (3.5)                   | 5 (5.9)                  |
| 3 times daily                                 | 10 (7.0)                  | 9 (10.6)                 |
| 4 times daily                                 | 61 (43.0)                 | 25 (29.4)                |
| 5–8 times daily                               | 21 (14.8)                 | 15 (17.6)                |
| >8 times daily                                | 10 (7.0)                  | 9 (10.6)                 |

study, patients received besifloxacin or moxifloxacin QID starting 3 days before surgery and continuing for 7 days postoperatively. Changes in central corneal thickness, endothelial cell count, and corneal staining, evaluated on postoperative days 7 and 28, were negligible with no difference between treatments. Finally, a prospective, contralateral eye, double-masked



**FIG. 2.** Rates of corneal scarring and corneal neovascularization.



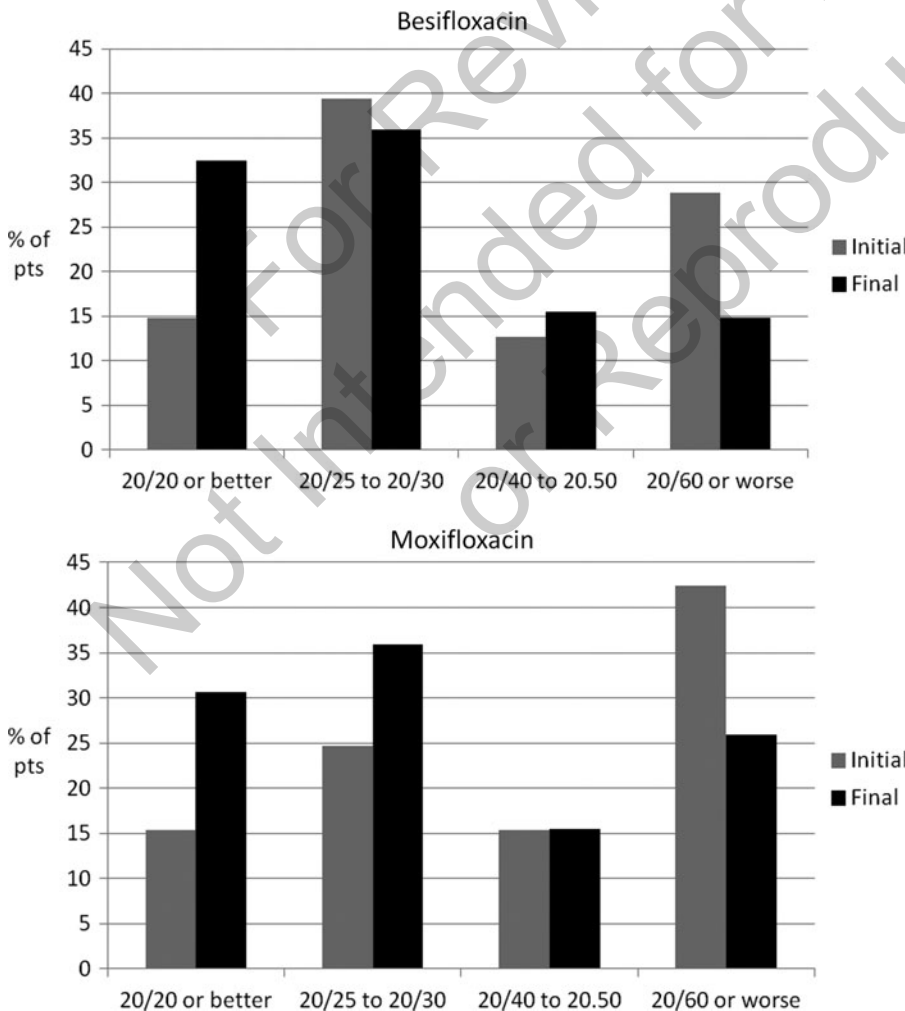
**FIG. 3.** Percentage of eyes with investigator-reported bacterial eradication after treatment with besifloxacin or moxifloxacin. Most reports were based on clinical observation.

study compared besifloxacin 0.6% and moxifloxacin 0.5%, both administered TID after placement of a bandage contact lens until healing, after photorefractive keratectomy in 40 patients (80 eyes). No complications were reported, and rates of epithelial wound healing were similar between the 2 treat-

ment groups (Donnenfeld E, et al., data presented at the 2013 meeting of the American Society of Cataract and Refractive Surgery).

Fluoroquinolones are increasingly being used for the treatment of bacterial keratitis and have been found to be safe and well tolerated. A meta-analysis of results from clinical trials conducted between 1991 and 2011 comparing second- and third-generation fluoroquinolones to fortified antibiotics found that fluoroquinolones were at least as effective (overall odds ratio of 1.473 [0.902–2.405]) with a better tolerance profile than fortified antibiotics when prescribed as empiric initial therapy for keratitis.<sup>37</sup>

Studies comparing fourth-generation fluoroquinolones with conventional fortified antibiotics in the treatment of bacterial keratitis also demonstrate similar efficacy with good safety and tolerability.<sup>13,38,39</sup> In these studies, therapy was typically initiated hourly for 2–3 days, tapered thereafter, and continued as long as needed rather than a predetermined duration, which is consistent with the varying lengths of treatment durations noted in our patients treated for keratitis. A clinical trial comparing the effectiveness of moxifloxacin or ofloxacin to a fortified tobramycin 1.33%/cephazolin 5% combination therapy reported similarly high resolution ( $P=0.13$ ) and healing rates ( $P=0.25$ ) for all treatment arms in cases of severe bacterial keratitis.<sup>13</sup> In another study, comparing moxifloxacin 0.5%, gatifloxacin



**FIG. 4.** Visual acuity findings, before and after treatment. pts, patients.

0.5%, and combined fortified tobramycin 1.3%/cefazolin 5% in bacterial keratitis patients with ulcer size between 2 and 8 mm, cure rates were 90% in the fortified antibiotics group versus 95% in both the gatifloxacin and moxifloxacin group ( $P=0.83$ ).<sup>39</sup> A recent clinical trial evaluating moxifloxacin 0.5% with a combination of fortified tobramycin 1.3%/cefazolin 5% combination therapy in the treatment of microbiologically proved cases of bacterial corneal ulcers found these treatments to be equivalent: Complete resolution of keratitis and healing of ulcers was reported for 81.8% of moxifloxacin-treated patients versus 81.4% of patients in the combination group at 3 months.<sup>38</sup> In each of these studies, fluoroquinolone treatment was safe and well tolerated, with no serious AEs attributable to therapy.

Treatment of keratitis sometimes entails concomitant use of NSAIDs and/or corticosteroids. Adjunctive NSAIDs have been shown effective in relieving ocular pain and inflammation in patients with corneal ulcers with no sign of delayed healing.<sup>40</sup> In our study, ophthalmic NSAIDs were utilized in a small number of eyes (4%). The Steroids for Corneal Ulcers Trial (SCUT) evaluated the use of topical prednisolone sodium phosphate 1.0% as adjunctive therapy in patients with bacterial keratitis receiving moxifloxacin 0.5%.<sup>41</sup> Although no overall difference in VA was noted at 3 months when topical corticosteroids were included, a significant benefit was shown in the subgroup of patients with the worst VA (counting fingers or worse) and central ulcer location at baseline ( $P\leq 0.04$ ). There were no significant safety findings from steroid use reported, and no delay in healing. In our study, adjunctive steroids were used in 11% of eyes.

The efficacy findings reported in this study were encouraging. Both besifloxacin and moxifloxacin were associated with high rates of physician-assessed bacterial eradication; however, since few clinicians confirmed their diagnosis and/or bacterial eradication through culture, and several patients in both treatment groups received additional treatments, further studies employing both pre- and post-treatment cultures isolating the therapeutic contribution of besifloxacin are warranted.

There has been an increase in MRSA as a causative pathogen in bacterial keratitis, particularly after keratorefractive surgery.<sup>42</sup> In this study, an efficacy assessment based on causative bacterial pathogen(s) was neither possible due to the limited corneal cultures collected (only in 11% of the cases) nor was the study designed to do so. Nevertheless, as indicated earlier, the effectiveness of besifloxacin against MRSA has been demonstrated in an experimental rabbit model of keratitis induced by MRSA,<sup>26</sup> suggesting that besifloxacin could be effective clinically against keratitis induced by that pathogen. In addition, *in vitro* studies have consistently demonstrated low minimum inhibitory concentrations (MICs) for besifloxacin against MRSA strains with MICs typically several-fold lower than comparator fluoroquinolones and similar to that of vancomycin.<sup>4,15,17,18</sup> This is particularly relevant given that an increase in MIC has been correlated with increased infiltrate/scar size of the cornea after treatment for keratitis. In a clinical trial of moxifloxacin ophthalmic solution 0.5% used for the treatment of bacterial keratitis, every 2-fold increase in MIC was associated with a 0.33 mm average diameter increase in scar size.<sup>43</sup> An association was not noted between MIC and VA or time to re-epithelialization.

The major limitation of this safety surveillance chart review is its retrospective nature. AEs were not captured

systematically as would happen in a prospective study; however, all events that were notable enough to be recorded in the patient chart were captured, and this process was the same for both besifloxacin and moxifloxacin. Thus, it is likely that most AEs of clinical relevance would have been reported. Data on the efficacy of besifloxacin and moxifloxacin when used in the treatment of keratitis were similarly restricted to chart documentation and were not a primary focus of the analysis.

Besifloxacin ophthalmic suspension 0.6% appeared to be a safe option for inclusion in the treatment of bacterial keratitis in this retrospective case study. Only one AE was reported despite the more frequent dosing and longer-term administration than what is recommended for the approved indication of bacterial conjunctivitis. These retrospective data also suggest good efficacy, although additional prospective clinical data isolating the contribution of besifloxacin are needed to confirm these observations.

### Acknowledgments

The authors wish to acknowledge the writing assistance of Carol Tozzi, PhD, of Churchill Communications (Maplewood, NJ). This assistance was funded by Bausch+Lomb.

### Study Investigators

G. Richard Cohen, MD (Boca Raton, FL); Ajeet Dhingra, MD (Decatur, GA); Kathryn Masselam Hatch, MD (Waltham, MA); David Kim, MD (Green Bay, WI); Charles Kirby, MD (Chattanooga, TN); Steven A. Nielsen, MD (Quincy, MA); Jai Parekh, MD (West Paterson, NJ); Barry Schechter, MD (Boynton Beach, FL); Zachary Segal, MD (Miami, FL); and William Trattler, MD (Miami, FL).

### Author Disclosure Statement

Dr. Barry Schechter declares a grant and provision of assistance with statistics with Bausch+Lomb. He also receives honorarium for consultancy from Bausch+Lomb, Omeros, Gerson Lehrman. Dr. Schechter lectures for payment for Allergan and Bausch+Lomb. Dr. Jai Parekh has consulted for Alcon, Allergan, and Bausch+Lomb over the past 2 years. Dr. William Trattler is a consultant for Bausch+Lomb and Allergan. There are no other relationships, conditions, or circumstances that present a potential conflict of interest for the authors mentioned here.

### References

1. Thomas, P.A., and Geraldine, P. Infectious keratitis. *Curr. Opin. Infect. Dis.* 20:129–141, 2007.
2. Bourcier, T., Thomas, F., Borderie, V., Chaumeil, C., and Laroche, L. Bacterial keratitis: predisposing factors, clinical and microbiological review of 300 cases. *Br. J. Ophthalmol.* 87:834–838, 2003.
3. Keay, L., Edwards, K., Naduvilath, T., et al. Microbial keratitis: predisposing factors and morbidity. *Ophthalmology.* 113:109–116, 2006.
4. Miller, D. Pharmacological treatment for infectious corneal ulcers. *Expert Opin. Pharmacother.* 14:543–560, 2013.
5. Marquart, M.E., and O'Callaghan, R.J. Infectious keratitis: secreted bacterial proteins that mediate corneal damage. *J. Ophthalmol.* 2013:Article ID 369094, 9 pages, 2003.

6. McLeod, S.D., Kolahdouz-Isfahani, A., Rostamian, K., Flowers, C.W., Lee, P.P., and McDonnell, P.J. The role of smears, cultures and antibiotic sensitivity testing in the management of suspected infectious keratitis. *Ophthalmology*. 103:23–28, 1996.
7. Miedziak, A.I., Miller, M.R., Rapuano, C.J., Laibson, P.R., and Cohen, E.J. Risk factors in microbial keratitis leading to penetrating keratoplasty. *Ophthalmology*. 106:1166–1170, 1999.
8. Vajpayee, R.B., Dada, T., Saxena, R., et al. Study of the first contact management profile of cases of infectious keratitis: a hospital-based study. *Cornea*. 19:52–56, 2000.
9. Chang, M.A., Jain, S., and Azar, D.T. Infections following laser *in situ* keratomileusis: an integration of the published literature. *Surv. Ophthalmol.* 49:269–280, 2004.
10. Wilhelmus, K.R., Hyndiuk, R.A., Caldwell, D.R., et al. 0.3% ciprofloxacin ophthalmic ointment in the treatment of bacterial keratitis. *Arch. Ophthalmol.* 111:1210–1218, 1993.
11. O'Brien, T.P., Maguire, M.G., Fink, N.E., Alfonso, E., McDonnell, P., and the Bacterial Keratitis Study Research Group. Efficacy of ofloxacin vs cefazolin and tobramycin in the therapy for bacterial keratitis: report from the Bacterial Keratitis Study Research Group. *Arch. Ophthalmol.* 113:1257–1265, 1995.
12. Ofloxacin Study Group. Ofloxacin monotherapy for the primary treatment of microbial keratitis: a double-masked, randomized, controlled trial with conventional dual therapy. *Ophthalmology*. 104:1902–1909, 1997.
13. Constantinou, M., Daniell, M., Snibson, G.R., Vu, H.T., and Taylor, H.R. Clinical efficacy of moxifloxacin in the treatment of bacterial keratitis. *Ophthalmology*. 114:1622–1629, 2007.
14. Ward, K.W., Lepage, J.-F., and Driot, J.-Y. Nonclinical pharmacodynamics, pharmacokinetics, and safety of BOL-3032243-A, a novel fluoroquinolone antimicrobial agent for topical ophthalmic use. *J. Ocul. Pharmacol. Ther.* 23:243–256, 2007.
15. Haas, W., Pillar, C.M., Zurenko, G.E., Lee, J.C., Brunner, L.S., and Morris, T.W. Besifloxacin, a novel fluoroquinolone, has broad-spectrum *in vitro* activity against aerobic and anaerobic bacteria. *Antimicrob. Agents Chemother.* 53:3552–3560, 2009.
16. Haas, W., Pillar, C., Hesje, C.K., Sanfilippo, C.M., and Morris, T.W. Bactericidal activity of besifloxacin against staphylococci, *Streptococcus pneumoniae* and *Haemophilus influenzae*. *J. Antimicrob. Chemother.* 65:1441–1447, 2010.
17. Haas, W., Gearinger, L.S., Usner, D.W., DeCory, H.H., and Morris, T.W. Integrated analysis of three bacterial conjunctivitis trials of besifloxacin ophthalmic suspension, 0.6%: etiology of bacterial conjunctivitis and antibacterial susceptibility profile. *Clin. Ophthalmol.* 5:1369–1379, 2011.
18. Haas, W., Pillar, C.M., Torres, M., Morris, T.W., and Sahm, D.F. Monitoring antibiotic resistance in ocular microorganisms: results from the ARMOR 2009 Surveillance Study. *Am. J. Ophthalmol.* 152:567–574, 2011.
19. Besivance Ophthalmic Suspension 0.6% [US Package Insert]. Tampa, FL: Bausch & Lomb, Inc.; 2009.
20. Cambau, E., Matrat, S., Xiao-Su, P., et al. Target specificity of the new fluoroquinolone besifloxacin in *Streptococcus pneumoniae*, *Staphylococcus aureus* and *Escherichia coli*. *J. Antimicrob. Chemother.* 63:443–450, 2009.
21. Sanfilippo, C.M., Hesje, C., Haas, W., and Morris, T.W. Topoisomerase mutations that are associated with high-level resistance to earlier fluoroquinolones in *Staphylococcus aureus* have less effect on the antibacterial activity of besifloxacin. *Chemotherapy*. 57:363–371, 2011.
22. Protzko, E., Bowman, L., Abelson, M., Shapiro, A., for the AzaSite Clinical Study Group. Phase 3 safety comparisons for 1.0% azithromycin in polymeric mucoadhesive eye drops versus 0.3% tobramycin eye drops for bacterial conjunctivitis. *Invest. Ophthalmol. Vis. Sci.* 48:3425–3429, 2007.
23. Bowman, L.M., Si, E., Pang, J., Archibald, R., and Friedlaender, M. Development of a topical polymeric mucoadhesive ocular delivery system for azithromycin. *J. Ocul. Pharmacol. Ther.* 25:133–139, 2009.
24. Akpek, E.K., Vittitow, J., Verhoeven, R.S., et al. Ocular surface distribution and pharmacokinetics of a novel ophthalmic 1% azithromycin formulation. *J. Ocul. Pharmacol. Ther.* 25:433–439, 2009.
25. Silverstein, B.E., Morris, T.W., Gearinger, L.S., DeCory, H.H., and Comstock, T.L. Besifloxacin ophthalmic suspension 0.6% in the treatment of bacterial conjunctivitis patients with *Pseudomonas aeruginosa* infections. *Clin. Ophthalmol.* 6:1987–1996, 2012.
26. Sanders, M.E., Norcross, E.W., Moore, Q.C., 3rd, Shafiee, A., and Marquart, M.E. Efficacy of besifloxacin in a rabbit model of methicillin-resistant *Staphylococcus aureus* keratitis. *Cornea*. 28:1055–1060, 2009.
27. Sanders, M.E., Moore, Q.C., 3rd, Norcross, E.W., Shafiee, A., and Marquart, M.E. Efficacy of besifloxacin in an early treatment model of methicillin-resistant *Staphylococcus aureus* keratitis. *J. Ocul. Pharmacol. Ther.* 26:193–198, 2010.
28. Sanders, M.E., Moore, Q.C., 3rd, Norcross, E.W., et al. Comparison of besifloxacin, gatifloxacin, and moxifloxacin against strains of *Pseudomonas aeruginosa* with different quinolone susceptibility patterns in a rabbit model of keratitis. *Cornea*. 30:83–90, 2011.
29. Michaud, L. Efficacy of besifloxacin in the treatment of corneal ulcer. *Clin. Refract. Optom.* 2011; 22:5–6.
30. Karpecki, P., DePaolis, M., Hunter, J.A., et al. Besifloxacin ophthalmic suspension 0.6% in patients with bacterial conjunctivitis: a multicenter, prospective, randomized, double-masked, vehicle-controlled, 5-day efficacy and safety study. *Clin. Ther.* 31:514–526, 2009.
31. McDonald, M.B., Protzko, E.E., Brunner, L.S., et al. Efficacy and safety of besifloxacin ophthalmic suspension 0.6% compared with moxifloxacin ophthalmic solution 0.5% for treating bacterial conjunctivitis. *Ophthalmology*. 116:1615–1623, 2009.
32. Tepedino, M.E., Heller, W.H., Usner, D.W., et al. Phase III efficacy and safety study of besifloxacin ophthalmic suspension 0.6% in the treatment of bacterial conjunctivitis. *Curr. Med. Res. Opin.* 25:1159–1169, 2009.
33. DeLeon, J., Silverstein, B.E., Allaire, C., et al. Besifloxacin ophthalmic suspension 0.6% administered twice daily for 3 days in the treatment of bacterial conjunctivitis in adults and children. *Clin. Drug Invest.* 32:303–317, 2012.
34. Nielsen, S.A., McDonald, M.B., and Majmudar, P.A. Safety of besifloxacin ophthalmic suspension 0.6% in refractive surgery: a retrospective chart review of post-LASIK patients [corrigendum in *Clin Ophthalmol.* 2013; 7:725]. *Clin. Ophthalmol.* 7:149–156, 2013.
35. Parekh, J.G., Newsom, T.H., and Nielsen, S. Safety of besifloxacin ophthalmic suspension 0.6% in cataract surgery patients. *J. Cataract Refract. Surg.* 38:1864–1867, 2012.
36. Malhotra, R., Gira, J., Berdy, G., et al. Safety of besifloxacin ophthalmic suspension 0.6% as a prophylactic antibiotic following routine cataract surgery: results of a

- prospective, parallel-group, investigator-masked study. *Clin. Ophthalmol.* 6:855–863, 2012.
37. Hanet, M.-S., Jamart, J., and Chaves, A.P. Fluoroquinolones or fortified antibiotics for treating bacterial keratitis: systematic review and meta-analysis of comparative studies. *Can. J. Ophthalmol.* 47:493–499, 2012.
  38. Sharma, N., Goel, M., Bansal, S., et al. Evaluation of moxifloxacin 0.5% in treatment of nonperforated bacterial corneal ulcers: a randomized controlled trial. *Ophthalmology.* 120:1173–1178, 2013.
  39. Shah, V.M., Tandon, R., Satpathy, G., et al. Randomized clinical study for comparative evaluation of fourth-generation fluoroquinolones with the combination of fortified antibiotics in the treatment of bacterial corneal ulcers. *Cornea.* 29:751–757, 2010.
  40. Schechter, B.A., and Trattler, W. Efficacy and safety of bromfenac for the treatment of corneal ulcer pain. *Adv Ther.* 27:756–761, 2010.
  41. Srinivasan, M., Mascarenhas, J., Rajaraman R, et al. Corticosteroids for bacterial keratitis: the Steroids for Corneal Ulcers Trial (SCUT). *Arch. Ophthalmol.* 130:143–150, 2012.
  42. Solomon, R., Donnenfeld, E.D., Holland, E.J., et al. Microbial keratitis trends following refractive surgery: results of the ASCRS infectious keratitis survey and comparisons with prior ASCRS surveys of infectious keratitis following keratorefractive procedures. *J. Cataract Refract. Surg.* 37:1343–1350, 2011.
  43. Chen, A., Prajna, L., Srinivasan, M., et al. Does *in vitro* susceptibility predict clinical outcome in bacterial keratitis? *Am. J. Ophthalmol.* 145:409–412, 2008.

Received: April 14, 2014  
Accepted: October 2, 2014

Address correspondence to:  
Dr. Barry A. Schechter  
Florida Eye Microsurgical Institute  
1717 Woolbright Road  
Boynton Beach, FL 33426

E-mail: [baschechter@gmail.com](mailto:baschechter@gmail.com)

For Review Only  
Not Intended for Distribution  
or Reproduction