

# Efficacy of Topical Cyclosporine for the Treatment of Ocular Rosacea

Barry A. Schechter

Received: February 23, 2009 / Published online: / Printed:  
© Springer Healthcare Communications 2009

## ABSTRACT

**Introduction:** This study was designed to compare the efficacy of cyclosporine ophthalmic emulsion 0.05% with an artificial tear solution for the treatment of rosacea-associated eyelid and corneal pathology. **Methods:** Double-masked, randomized, 3-month clinical trial of 37 patients with rosacea-associated eyelid and corneal changes (defined as lid margin telangiectasia, meibomian gland inspissation, and/or fullness of the lid margin). All findings were standardized and compared to photographs for grading. **Results:** There was a statistically significant increase in Schirmer (with anesthesia) scores of  $2.7 \pm 2.2$  mm after 3 months of treatment in the topical cyclosporine group ( $P < 0.001$ ), compared with a mean decrease of  $-1.4 \pm 4.6$  mm ( $P = 0.271$ ) in the artificial tears group. The mean tear break-up time score significantly improved in the topical cyclosporine group (mean increase of  $3.56 \pm 1.5$  seconds,  $P < 0.001$ ), but worsened in the control group, although this change was not significantly

significant (mean decrease of  $-0.04 \pm 1.6$  seconds,  $P = 0.929$ ). The topical cyclosporine group exhibited a significantly greater mean reduction in corneal staining scores ( $-1.3 \pm 0.53$ ) compared with the control group ( $-0.2 \pm 0.83$ ; between groups  $P < 0.001$ ). The topical cyclosporine group had a greater improvement in Ocular Surface Disease Index scores than those using artificial tears ( $P = 0.022$ ). Limitations of the study included an older, predominantly Caucasian patient population and short trial length. **Conclusions:** Topical cyclosporine 0.05% is more effective than artificial tears for the treatment of rosacea-associated lid and corneal changes.

**Keywords:** artificial tears; cyclosporine; meibomian gland; ocular rosacea; telangiectasia

## INTRODUCTION

Rosacea is a common ocular cutaneous disorder, primarily affecting the sebaceous glands of the face and the meibomian glands of the eyelids. Recent studies estimate that ocular pathology in this potentially blinding condition affects between 6% and 18% of patients with acne rosacea.<sup>1</sup> Despite the substantial impact on quality of life and significant

---

Barry A. Schechter (✉)  
Florida Eye Microsurgical Institute, 1717 W. Woolbright  
Road, Boynton Beach, Florida, FL 33426, USA.  
Email: bdsch77@aol.com

morbidity of ocular rosacea, few patients with the disease are treated by an ophthalmologist.<sup>1</sup> Ocular symptoms of rosacea range from neovascularization to mild blepharoconjunctivitis.<sup>2</sup> Most subjects present with complaints of foreign body sensations, pain, or burning; bilateral presentation is common, but unilateral involvement has also been noted.<sup>3</sup> The ocular manifestations of this disease routinely produce tear film abnormalities, which result in blurred vision, tearing, and burning. Tear film instability, characterized by rapid tear break-up time (TBUT), leads to decreased tear production and function.<sup>4</sup> As a result, the corneal and conjunctival epithelia of patients with ocular rosacea often exhibit significant pathology compared with healthy subjects.<sup>5</sup>

Rosacea primarily manifests itself as a cutaneous vascular disorder, and inflammatory changes are a hallmark of severe rosacea. These later stages are marked by inflammatory changes in the form of papules and pustules in the midface, rhinophyma, blepharitis, meibomitis, and corneal vascularization. The precise pathophysiology remains unknown, and theories have ranged from cell-mediated immune response to *Demodex* to a resemblance to type-IV hypersensitivity reaction.<sup>3</sup> Whatever the cause, abnormal sebaceous glands lead to the ocular inflammation. Barton et al.<sup>6</sup> found a significantly higher concentration of tear interleukin-1 $\alpha$  in subjects with ocular rosacea compared with subjects without the disease, and theorized the increase was resultant of the clearance failure of the cytokine.

Meibomian gland disease (MGD) is often an ocular finding of patients with rosacea.<sup>3</sup> MGD can occur on its own, but secondary MGD is typically associated with acne rosacea, atopic dermatitis, and/or seborrheic dermatitis.<sup>7</sup>

Further complicating treatment success is the considerable overlap noted in patients with

blepharitis, MGD, and dry eye.<sup>8</sup> Treatment of the cutaneous manifestations of rosacea (ie, metronidazole gel) alone will not alleviate the risk of visual loss that can result from ocular rosacea, and an ophthalmic directed approach is necessary.<sup>9,10</sup>

Artificial tears have long been used for chronic management of dry eye symptoms. However, these drops provide insufficient long-term symptomatic relief in most patients and fail to address the underlying pathology. If the patient does not respond adequately to artificial tear treatment, stepwise management indicates lubricating ointments, doxycycline (if indicated for MGD) or topical cyclosporine; should those therapies prove unsuccessful, surgical intervention may be necessary.<sup>11</sup>

Nonpreserved artificial tears are often prescribed for the treatment of ocular rosacea.<sup>3</sup> However, no single therapeutic regimen has been found effective in all cases of ocular rosacea, and many cases are recalcitrant to multiple therapies.<sup>11</sup> For example, patients with ocular rosacea who are asymptomatic and without worsening eye disease should not be put on oral antibiotics (which may cause systemic adverse events). In addition, tetracyclines are contraindicated or not safe in pregnancy in patients with ocular rosacea.<sup>11</sup>

Systemic cyclosporine has been used extensively as an immunosuppressant in organ transplant patients; studies have shown the compound able to effectively inhibit T-lymphocyte activation/migration, and further research found it can inhibit cell apoptosis as well.<sup>12</sup> Topical cyclosporine 0.05% has only been contraindicated in patients with active ocular infections, as approved for dry eye treatment.<sup>13,14</sup> Topical cyclosporine 0.05% has been shown to increase tear production and improve the quality of naturally produced tears with no adverse effect on visual acuity,

and is the first approved therapeutic agent for the treatment of chronic dry eye.<sup>13</sup> Topical cyclosporine 0.05% has also been shown to significantly reduce the number of activated lymphocytes within the conjunctiva.<sup>14</sup> The study by Kunert et al.<sup>15</sup> provided evidence that inflammation plays a role in the pathogenesis of dry eye and that modulating the underlying immune response may be more effective than frequent dosing with artificial tears. Patients with childhood ocular rosacea refractory to steroid treatment have been treated effectively with topical cyclosporine 2%.<sup>16</sup>

The purpose of this study was to compare the efficacy of topical cyclosporine 0.05% with an artificial tear solution for the treatment of rosacea-associated eyelid and corneal changes. For the purposes of this study, "rosacea-associated eyelid and corneal changes" were defined as lid margin telangiectasia, meibomian gland inspissation, and/or fullness of the lid margin. All the findings were standardized and compared to photographs for grading.

## MATERIALS AND METHODS

This study was a multiple-site, randomized, double-masked clinical trial. Patients ( $n=37$ ) with rosacea-associated eyelid and corneal changes were enrolled. Patients had a diagnosis of ocular-associated rosacea confirmed by a dermatologist. Any patients with active infections were treated with lid scrubs and antibiotics prior to enrollment. All patients were withdrawn from oral doxycycline for at least 2 weeks prior to study entry, and patients with eyelid defects or lagophthalmos were excluded. Any patients who demonstrated sensitivity to either study medication were excluded. Pregnant women or nursing mothers were not enrolled. After infections were clinically controlled, patients were randomized by computer

to cyclosporine twice daily or artificial tears twice daily for 3 months. It should be noted that the vials for each product are identical when the labels are removed, ensuring patient and clinician masking.

At each visit, patients were assessed by the Ocular Surface Disease Index (OSDI) questionnaire. The OSDI is a standardized, validated patient questionnaire designed to determine the impact of ocular surface disease (normal, mild to moderate, and severe) on patient quality of life. The index is assessed on a scale of 0 to 100, with higher scores representing greater disability. It demonstrates sensitivity and specificity in distinguishing between normal subjects and patients with dry eye disease.<sup>17</sup> In addition to the OSDI, patients also underwent Schirmer testing with local anesthesia (bilateral, simultaneous for 3 minutes), measurement of corneal staining, and TBUT at each study visit. After completing the TBUT evaluation (fluorescein solution was instilled and covered the ocular surface; after several blinks, the amount of time until a bare area on the cornea appeared was noted), the entire cornea was examined for staining using the yellow barrier filter and the slit lamp's cobalt blue illumination with a 3 mm slit width and 16 $\times$  magnification. (The yellow barrier filter is the researchers' standard filter used when fluorescein dye is used or present on the ocular surface.) Corneal fluorescein staining was evaluated only after 30 seconds but before 2 minutes had elapsed following the instillation of the fluorescein. Staining was scored using an Oxford staining scale evaluating the five regions of the cornea and two in the conjunctiva. Bron et al.<sup>18</sup> described the Oxford Scheme for grading ocular surface staining in dry eye, and staining in this study followed those parameters. The total score was the sum of each of these sections.

The number of meibomian glands expressed (due to inspissation) and the quality of the excreta were also evaluated at each study visit. The actual number of meibomian glands expressed was recorded and the excreta quality was graded on a scale of 1-4 (where 1=clear excreta or clear with small particles; 2=opaque excreta with normal viscosity; 3=opaque excreta with increased viscosity; 4=secretions retain shape after expression).

Changes from baseline were described at follow-up visits, and final patient success was evaluated at the month-3 visit. Patients who were still symptomatic after their initial regimen (at the month-3 evaluation) were offered a switch to the alternate regimen and returned for a follow-up assessment in 1 month. All measurement values are expressed as the mean  $\pm$  SD.

The protocol was in compliance with Good Clinical Practice guidelines and the Declaration of Helsinki (1996), and in accordance with applicable institutional review board regulations (United States 21 Code of Federal Regulations [US 21 CFR] part 56.103). Study participants gave informed consent prior to initiation of any study-related procedures. The study was performed in compliance with informed consent regulations (US 21 CFR part 50) and was in accordance with Health Insurance Portability and Accountability Act (HIPAA) regulations and all relevant institutional review board approvals were also obtained.

### Statistical Analysis

Mean changes in continuous outcome measures within each treatment group were analyzed by paired sample *t* tests. Between-group differences were evaluated with two-sample *t* tests. The a-priori alpha level for all tests was  $P=0.05$ .

## RESULTS

### Patient Demographics

The mean age of the patients enrolled in the topical cyclosporine arm was 75.6 years ( $n=21$ ), compared with a mean age of 69.6 years in the artificial tears arm ( $n=16$ ). As the primary recruitment site was in Florida, we expected an older patient population. All but one of the patients was Caucasian.

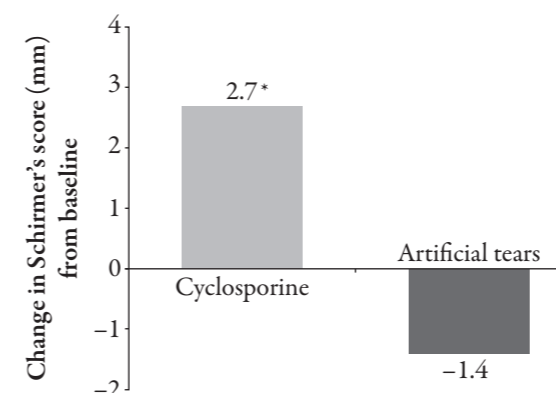
All patients were symptomatic and demonstrated classic ocular changes of rosacea (such as lid margin telangiectasia and meibomian gland inspissation) as determined by the dermatologist and confirmed by an ophthalmologist. Patients were enrolled sequentially as they were diagnosed in clinic with rosacea.

There were no significant between-group differences in any patient demographic variable (Table 1). There was no significant between-group difference in mean Schirmer scores at the initial visit ( $9.7\pm 5.1$  mm in the cyclosporine group, compared with  $10.2\pm 5.8$  mm in the artificial tears group;  $P=0.765$ ). After 3 months there was a statistically significant increase in Schirmer scores of  $2.7\pm 2.2$  mm ( $P<0.001$ ) in the patients dosed with topical cyclosporine. Conversely, Schirmer scores worsened in the artificial tears group, with a mean decrease of  $-1.4\pm 4.6$  mm ( $P=0.271$ ). The improvement in

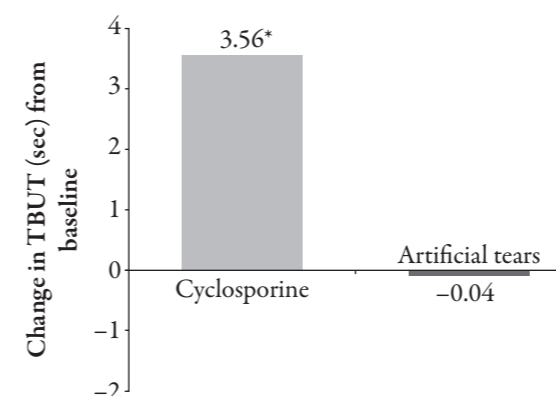
**Table 1.** Patient demographics.

	Cyclosporine	Artificial tears
No. of patients	21	16
Mean age, years	75.6	69.6
Gender, <i>n</i>		
Male	15	9
Female	6	7
Race, <i>n</i>		
Caucasian	20	16
Black	1	0

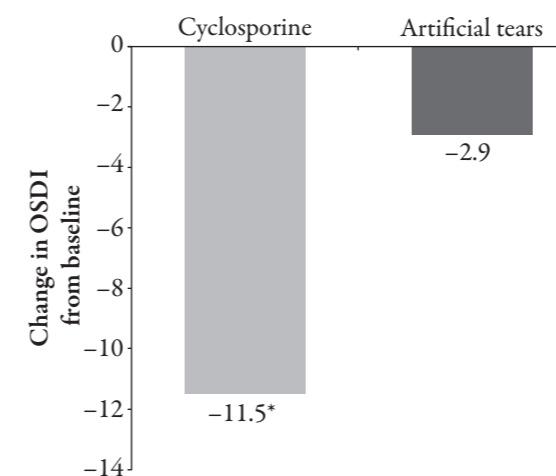
**Figure 1.** Mean change in Schirmer scores (with anesthesia) from initial visit to after 3 months of treatment. \* $P=0.002$ .



**Figure 2.** Mean change in tear break-up time (TBUT) scores from initial visit to after 3 months of treatment. \* $P<0.001$ .



**Figure 3.** Change in Ocular Surface Disease Index (OSDI) scores from initial visit after 3 months of treatment. \* $P=0.022$ .



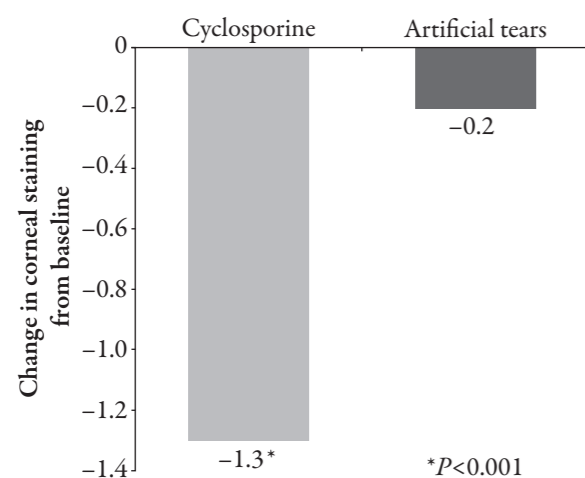
the mean Schirmer score was statistically significantly greater in the cyclosporine group than in the artificial tears group ( $P=0.002$ ) (Figure 1).

Although there were no significant between-group differences in mean TBUT scores at the initial study visit in the topical cyclosporine-treated group and the artificial tear-treated group ( $5.83\pm 3.6$  seconds compared with  $5.46\pm 3.6$  seconds, respectively;  $P=0.776$ ), 3 months of cyclosporine improved mean TBUT scores more than artificial tears ( $P<0.001$ ). Mean TBUT scores improved in the cyclosporine-treated patients (mean increase of  $3.56\pm 1.5$  seconds,  $P<0.001$ ; Figure 2). However, mean TBUT scores slightly worsened in the tears group, although the difference was not statistically significant (mean decrease of  $-0.04\pm 1.6$  seconds,  $P=0.929$ ).

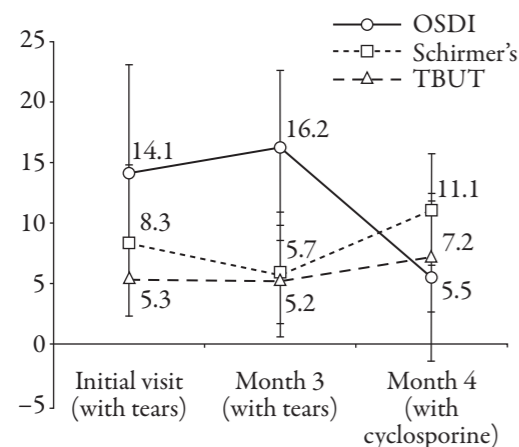
There was no significant difference between groups in mean OSDI scores at the initial study visit in the topical cyclosporine-treated group and the artificial tear-treated group ( $19.1\pm 13.9$ , compared with  $16.9\pm 15.8$ , respectively;  $P=0.671$ ). Three months of cyclosporine improved mean OSDI scores significantly more than 3 months of artificial tears ( $P=0.022$ ). Cyclosporine-treated patients had a mean reduction (improvement) in OSDI scores of  $-11.5\pm 8.8$ , while patients who used artificial tears had a mean decrease of  $-2.9\pm 11.6$ , ( $P=0.348$ , Figure 3).

Mean corneal staining scores at the initial study visit were similar in the topical cyclosporine-treated group and the artificial tear-treated group ( $1.4\pm 0.8$ , compared with  $0.9\pm 0.7$ , respectively;  $P=0.064$ ). Three months of cyclosporine usage reduced corneal staining significantly more than 3 months of artificial tears ( $P<0.001$ ). The mean reduction in corneal staining was  $-1.3\pm 0.53$  in the cyclosporine-treated patients ( $P<0.001$ ) compared with a mean reduction of  $-0.2\pm 0.83$  in the artificial tear-treated patients ( $P=0.328$ , Figure 4).

**Figure 4.** Change in mean corneal staining from initial visit after 3 months of treatment. \* $P < 0.001$ .



**Figure 5.** Evaluation of rosacea-associated ocular signs and symptoms in patients nonresponsive to artificial tear therapy who then switched to cyclosporine for 1 month.



None of the patients treated with artificial tears experienced satisfactory resolution of their signs or symptoms. Seven of the 15 patients who were randomized to artificial tears and completed the month-3 study visit agreed to switch to cyclosporine therapy and return in 1 month for a final follow-up study visit (Figure 5). Patients who switched from artificial tears to cyclosporine had a statistically significant improvement in mean OSDI score ( $P = 0.001$ ), Schirmer score ( $P = 0.003$ ), and TBUT ( $P = 0.008$ ) from the end of

artificial tear treatment to the 1-month analysis after beginning treatment with topical cyclosporine. Patients had a mean (pretreatment with either therapy) OSDI score of  $14.1 \pm 8.96$  at baseline,  $16.2 \pm 6.41$  after 3 months of artificial tear treatment, and  $5.5 \pm 6.93$  after 1 month of topical cyclosporine. Patients had a mean Schirmer score of  $8.3 \pm 6.04$  at baseline,  $5.7 \pm 5.14$  after 3 months of artificial tear treatment, and  $11.1 \pm 4.64$  after 1 month of topical cyclosporine. TBUT scores improved from a mean of  $5.2 \pm 3.45$  after 3 months of artificial tear treatment to  $7.2 \pm 4.54$  after 1 month of topical cyclosporine treatment. Patients also demonstrated a statistically significant improvement in corneal staining ( $P = 0.012$ ) after switching from 3 months of using artificial tears to 1 month of cyclosporine. They progressed from 0.86 at the initial visit, to 0.79 after 3 months of artificial tears, to 0.14 after 1 month of topical cyclosporine.

#### Other Outcome Measures

After 3 months of treatment, the mean number of unoccluded, expressible meibomian glands increased from  $3.95 \pm 2.22$  at baseline to  $6.67 \pm 2.16$  in the cyclosporine group but was unchanged in the artificial tears group (mean reduction of  $0.03 \pm 0.61$ ). The difference between the groups was statistically significant ( $P < 0.001$ ).

Although not a primary outcome measure, both treatments were well tolerated, and there was a high rate of completion in each study group (90.5% in the topical cyclosporine group and 93.8% in the artificial tear group). Only three patients exited the study prior to the month-3 visit. In the cyclosporine group, one patient was lost to follow-up and one patient discontinued, complaining of "stinging" upon instillation. In the tears group, one patient was lost to follow-up.

## DISCUSSION

In the present study, topical cyclosporine 0.05% provided statistically significantly greater improvements in Schirmer scores, OSDI, TBUT, and corneal staining scores than artificial tears on rosacea-associated eyelid and corneal changes. The improvements seen with topical cyclosporine are most likely due to the effects topical cyclosporine 0.05% has on increasing tear production and decreasing inflammation.<sup>13</sup> Furthermore, the ability of topical cyclosporine 0.05% to significantly improve Schirmer scores, OSDI, TBUT, and corneal staining scores may be due to a cyclosporine-mediated reduction in the number of activated lymphocytes within the conjunctiva.<sup>15</sup> By reducing activated lymphocytes and increasing tear production, topical cyclosporine 0.05% decreases inflammation within the eye and improves patient signs and symptoms.

Ocular rosacea is an inflammatory disease as well, sometimes associated with MGD. Traditional treatments for both diseases include lid hygiene, oral tetracyclines, steroids, and antibiotics. Ocular rosacea, however, is more involved than MGD; the latter can be (mis)diagnosed as dry eye,<sup>19</sup> while the former is a manifestation of a dermatologic disorder. Both, however, are strongly associated with age.<sup>3,19</sup> It is not surprising that subjects in this study presented with both ocular rosacea and MGD, as the geographic location of this study yields an older demographic. Zengin et al.<sup>20</sup> also found a strong correlation between rosacea and MGD. In that study, patients with poor meibum secretion and inspissation exhibited tear film instability and experienced premature tear evaporation.

Barton et al.<sup>6</sup> noted reduced tear turnover, its inverse correlation with interleukin-1 $\alpha$ , and the absence of tumor necrosis factor- $\alpha$  in the tears of patients with ocular rosacea,

suggested that the increased concentration of interleukin-1 $\alpha$  observed may be largely because of clearance failure of cytokines normally produced at the ocular surface. A separate study suggested that after 6 months of use, topical cyclosporine was shown to decrease inflammatory cytokines in the conjunctival epithelium of dry eye patients.<sup>21</sup>

Despite the relatively common incidence of ocular rosacea, the diagnosis is routinely missed by ophthalmologists or, when it is made, often undertreated. Akpek et al.<sup>3</sup> describes the non-specific nature of these signs and symptoms is likely to contribute to the possibility of misdiagnosis. However, this same report underscores the potential consequences of undertreating ocular rosacea. Although the majority of patients (86.3%, 113/131) studied received oral tetracycline (a common treatment for rosacea), 13 patients had decreased visual acuity at the time of presentation due to corneal complications. Six of these patients required penetrating keratoplasty during the course of their disease. Seven patients had severe cicatrizing conjunctivitis at the time of referral and seven patients were left with visual acuity less than 20/400. One patient underwent enucleation for corneal perforation and endophthalmitis.<sup>3</sup> Early treatment to avoid severe visual complications associated with both ocular rosacea and MGD is recommended, and prolonged treatment may be necessary.<sup>3,7,16,22</sup>

The finding that cyclosporine is an effective treatment for the signs and symptoms of ocular rosacea is consistent with another study. Perry et al.<sup>22</sup> reported that topical cyclosporine was effective in treating ocular rosacea patients who were unresponsive to standard therapy. Moreover, most patients in that cohort (71%) were able to discontinue all other medications. These authors also found that topical cyclosporine was safe and well tolerated in



patients with ocular rosacea. Perry et al.<sup>22</sup> also found several objective examination findings between the placebo and topical cyclosporine groups to be statistically significant at the 3-month visit, including lid margin vascular injection, tarsal telangiectasia, and fluorescein staining (all  $P < 0.05$ ). The most significant of changes ( $P = 0.001$ ) was the greater decrease in the number of occluded meibomian glands in the cyclosporine group as compared with the placebo group.<sup>23</sup>

This study was not without limitations. The patient groups were older and Caucasian, and therefore any results gleaned from this study may not be applicable to younger patients or those of different ethnicities. The relatively small sample size and results may not necessarily be replicated in a larger-scale trial.

The authors recommend that future studies compare topical cyclosporine 0.05% and tetracycline for the treatment of ocular rosacea, as tetracycline is often most prescribed, but is not without potential for adverse events. Comparing topical cyclosporine 0.05% to other antibiotics used in the treatment of rosacea/ocular rosacea and/or MGD is also recommended. Other beneficial future studies might include comparisons between topical cyclosporine and more than one artificial tear lubricant, and to compare topical cyclosporine 0.05% to oral tetracycline for the treatment of ocular rosacea patients. In addition, a larger-scale, longer-duration study to determine the long-term efficacy of topical cyclosporine 0.05% (ie, prevention of flare-ups) for the treatment of ocular rosacea would be beneficial.

## CONCLUSION

Topical cyclosporine 0.05% is more effective than artificial tears for the treatment of rosacea-associated lid and corneal changes.

## ACKNOWLEDGMENTS

The author wishes to acknowledge IMEDS for assistance in the statistical analysis and in the preparation of the paper.

This paper was presented in part at the Annual Meeting of the Association for Research in Vision and Ophthalmology; May 1-5, 2005, Fort Lauderdale, Florida, USA.

**Declaration of interest:** This study was funded by an unrestricted educational grant from Allergan, Inc.

## REFERENCES

- Ghanem VC, Mehra N, Wong S, Mannis MJ. The prevalence of ocular signs in acne rosacea: comparing patients from ophthalmology and dermatology clinics. *Cornea*. 2003;22:230-233.
- Marmion VJ. Tetracyclines in the treatment of ocular rosacea. *Proc R Soc Med*. 1969;62:11-12.
- Akpek EK, Merchant A, Pinar V, Foster CS. Ocular rosacea: patient characteristics and follow-up. *Ophthalmology*. 1997;104:1863-1867.
- Bowman RW, McCulley JP, Jester JV. Meibomian gland dysfunction and rosacea. In: Pepose J, Holland G, Wilhelmus K, eds. *Ocular Infection and Immunity*. St. Louis: Mosby-Year Book; 1996:334-343.
- Kocak-Altintas AG, Kocak-Midillioglu I, Gul U, et al. Impression cytology and ocular characteristics in ocular rosacea. *Eur J Ophthalmol*. 2003;13:351-359.
- Barton K, Monroy DC, Nava A, Pflugfelder SC. Inflammatory cytokines in the tears of patients with ocular rosacea. *Ophthalmology*. 1997;104:1868-1874.
- Bron AJ. Diagnosis of meibomian gland disease and MKC: what is really meant by meibomian inflammation? *Am J Ophthalmol*. 2005;139:S23-S24.
- Macasai M. The role of Omega-3 dietary supplementation in blepharitis and meibomian gland dysfunction (an AOS thesis). *Trans Am Ophthalmol Soc*. 2008;106:336-356.
- Jansen T, Plewig G. Rosacea: classification and treatment. *J R Soc Med*. 1997;90:144-150.

- Wilken J, Dahl M, Detmar M, et al. Standard classification of rosacea: report of the National Rosacea Society Expert Committee on the classification and staging of rosacea. *J Am Acad Dermatol*. 2002;46:584-587.
- Randleman JB, Loft E, Song CD. Ocular rosacea. Available at: <http://www.emedicine.com/oph/topic115.htm>. Accessed Nov. 7, 2006.
- Donnenfeld E, Pflugfelder SC. Topical ophthalmic cyclosporine: Pharmacology and clinical uses. *Surv Ophthalmol*. 2009;54:321-338.
- Sall K, Stevenson OD, Mundorf TK, Reis BL. Two multicenter, randomized studies of the efficacy and safety of cyclosporine ophthalmic emulsion in moderate to severe dry eye disease. *Ophthalmology*. 2000;107:631-963. Erratum in: *Ophthalmology*. 2000;107:1220.
- Restasis [package insert]. Irvine, CA: Allergan Inc.; 2004.
- Kunert KS, Tisdale AS, Stern ME, et al. Analysis of topical cyclosporine treatment of patients with dry eye syndrome: effect on conjunctival lymphocytes. *Arch Ophthalmol*. 2000;118:1489-1496.
- Doan S, Gabison E, Gatineau D, Duong M-H, Abitbol O, Hoang-Xuan T. Topical cyclosporine A in severe steroid-dependent childhood phlyctenular keratoconjunctivitis. *Am J Ophthalmol*. 2006;141:62-66.
- Schiffman RM, Christianson MD, Jacobsen G, et al. Reliability and validity of the Ocular Surface Disease Index. *Arch Ophthalmol*. 2000;118:615-621.
- Bron AJ, Evans VE, Smith JA. Grading of corneal and conjunctival staining in the context of other dry eye tests. *Cornea*. 2003;22:640-650.
- Driver PJ, Lemp MA. Meibomian gland dysfunction. *Surv Ophthalmol*. 1996;40:343-367.
- Zengin N, Tol H, Gunduz K, et al. Meibomian gland dysfunction and tear film abnormalities in rosacea. *Cornea*. 1995;14:144-146.
- Turner K, Pflugfelder SC, Ji Z, et al. Interleukin-6 levels in the conjunctival epithelium of patients with dry eye disease treated with cyclosporine ophthalmic emulsion. *Cornea*. 2000;19:492-496.
- Perry HD, Wittpenn JR, D'Aversa G, Donnenfeld ED. Topical cyclosporine 0.05% for the treatment of chronic, active ocular rosacea. Poster presented at: Annual Meeting of the Association for Research in Vision and Ophthalmology; May 3, 2005; Ft. Lauderdale, Florida, USA.
- Perry HD, Doshi-Carnevale S, Donnenfeld ED, et al. Efficacy of commercially available topical cyclosporine A 0.05% in the treatment of meibomian gland dysfunction. *Cornea*. 2006;25:171-175.